

Technical Innovation

Optimal Positioning for MRI of the Distal Biceps Brachii Tendon: Flexed Abducted Supinated View

B. M. Giuffrè¹ and M. J. Moss

The distal biceps brachii tendon is an uncommon site for tendon injury, representing 3% of all injuries of the biceps brachii tendon in the literature [1, 2]. There have been many suggestions for optimally imaging the elbow using MRI [3–8]. Axial imaging is often used, providing short-axis images of the tendon, to accurately show the anatomy and disease of the distal biceps tendon. In many circumstances, a long-axis image of the tendon is also useful. On direct sagittal images with the elbow extended, the distal biceps brachii tendon usually suffers from partial volume-average effects because of its oblique course to its insertion. We describe a novel way of positioning the patient with the shoulder abducted, elbow flexed, and forearm supinated. This allows us to obtain images of the distal biceps brachii tendon from the musculotendinous junction to its insertion, usually on a single image.

Materials and Methods

Imaging was performed on a 1.5-T MRI scanner (Signa Horizon LX, release 9.0, General Electric Medical Systems) with either the extremity coil or the dedicated shoulder phased array coil. In general, it was preferable for the patient to lie prone for these views. The shoulder was abducted 180°, with the arm beside the head. The elbow was flexed to 90°, with the forearm supinated, thumb up, and a shoulder phased array coil was placed around the elbow (Fig. 1). The position is referred to in this article as the flexed abducted supinated view, but usually in our practice it is termed the “FABS view,” meaning the flexed elbow with the shoulder abducted and the forearm in supination view.

We initially performed a three-plane localizer, with either three or five images in the axial, sagittal, and coronal planes. The coronal localizer images (sagittal elbow anatomy) were used to plan the sequences along the long axis of the distal biceps brachii tendon (along the line of the tendon if it is visible). If the tendon was not clearly seen on the localizer images, the series was planned nearly perpendicular to the radius, which was always clearly seen (Fig. 2). The normal flexed abducted supinated view showed the full length of the tendon (Fig. 3). Images in axial, and in some cases sagittal, planes were then also obtained with the shoulder in abduction and the elbow extended in the overhead position. It is also possible to obtain the axial and sagittal images with the arm by the side. Series with and without fat suppression were performed (proton density fast spin echo; TR/TE, 3,000/34 or 45) along the axis of the tendon (elbow flexed) and axial to the elbow joint (elbow extended). The field of view was 15 × 15 cm, and the slice thickness was 3 or 4 mm with interslice spacing of zero. For the flexed abducted supinated view, usually 18 slices were obtained with an approximate examination time of 2 min 40 sec.

Results

The MR images were independently reviewed by two radiologists experienced in musculoskeletal imaging. We have imaged, using the flexed abducted supinated view, 21 symptomatic patients with possible distal biceps brachii tendon problem. In one case, both elbows were symptomatic and were imaged. These patients were 32–81 years old (mean age, 52 years) and were imaged over the period from May 2001 to May 2003. Six asymptomatic healthy male volunteers (age range, 31–48 years) were also imaged using both traditional sagittal and flexed abducted supinated positions.

Three cases among 22 elbows in the study group exhibited normal distal biceps brachii tendons; in 14 cases, evidence of a partial tear or tendinosis of the distal biceps brachii tendon (Figs. 4 and 5) was present; in four cases, a complete tear (Fig. 6) was present; and in one case, an intact repaired complete tear was seen. In all cases, the full length of the biceps brachii tendon from musculotendinous junction to insertion on the radial tuberosity could be shown in one or, at most, two sections. In the 13 cases in which sagittal series were also performed, a single section less commonly ($n = 8$) showed the full tendon in one or two sections.

In four of these six asymptomatic volunteer evaluations, the flexed abducted supinated view showed the complete length of the tendon in one section; in the other two cases, it was seen in two sections. In the sagittal series of the healthy volunteers, the full tendon was seen in one section in only two cases.

Discussion

The distal biceps brachii tendon commences on the ventral surface of the muscle belly, approximately 5 cm above the elbow, and inserts on the radial tuberosity. The tendon is a flattened cord approximately 10 cm in length that rotates as it approaches its insertion, the ventral surface turning to lie on the radial side. The course is oblique, both superficial–deep and ulnar–radial. An aponeurotic extension, the bicipital aponeurosis, extends medially from the musculotendinous junction to blend with the deep fascia over the pronator teres muscle belly.

Received August 8, 2003; accepted after revision October 6, 2003.

¹Both authors: Department of Diagnostic Radiology, Royal North Shore Hospital, St. Leonards, NSW 2060, Australia. Address correspondence to B. M. Giuffrè (brunog@med.usyd.edu.au).

AJR 2004;182:944–946 0361–803X/04/1824–944 © American Roentgen Ray Society

MRI of the Distal Biceps Brachii Tendon

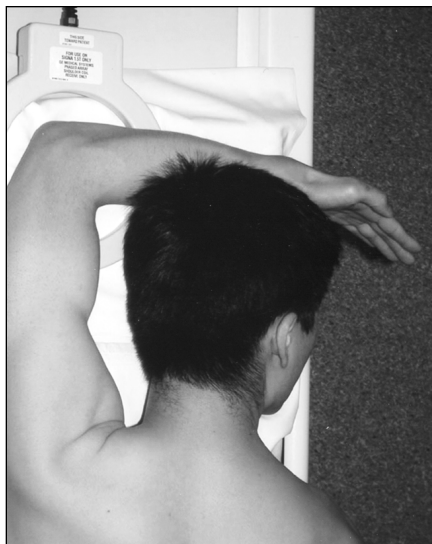


Fig. 1.—Photograph shows patient positioning for flexed abducted supinated view: patient is positioned prone on MRI table with elbow in flexed abducted supinated view position. Notice position of arm, flexed at elbow and abducted at shoulder with supinated forearm, thumb up.

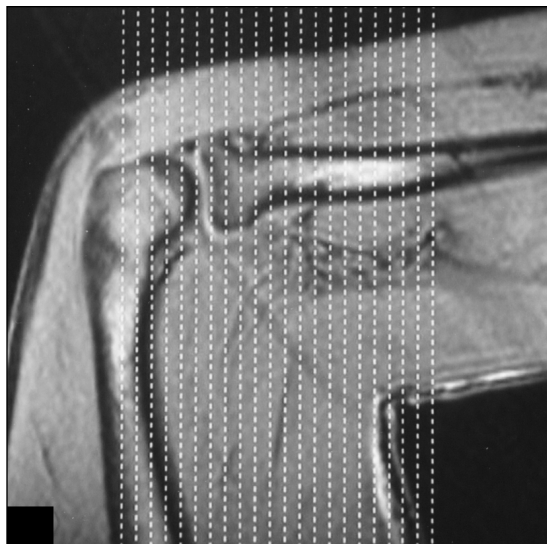


Fig. 2.—Localizer MR image with lines shows slice positioning for flexed abducted supinated view. Notice sections, sagittal to long axis of body but coronal to anatomy at elbow. Ideal angulation is planned along distal biceps brachii tendon, but often, as here, this structure is not clearly visible on localizer images. In this case, sections nearly perpendicular to radius provide reasonable and reproducible imaging plane.

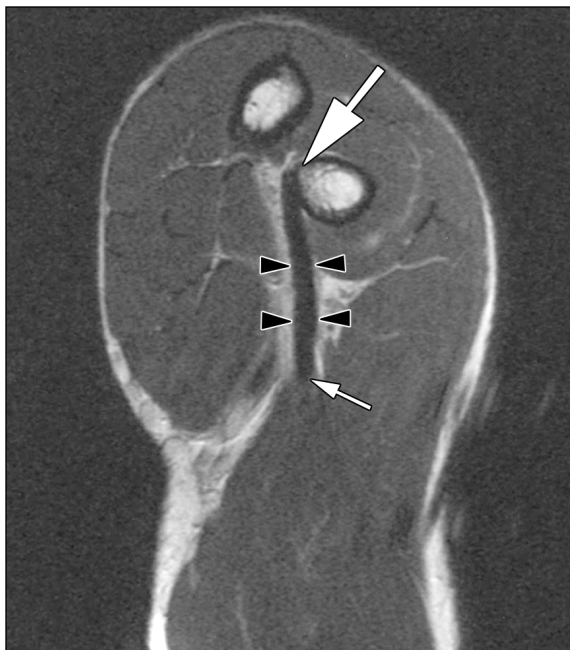


Fig 3.—32-year-old healthy male volunteer. Proton density-weighted MR image (TR/TE, 3,000/34) of normal flexed abducted supinated view of distal biceps brachii tendon shows straight course of tendon from musculotendinous junction to insertion and homogeneous low signal of tendon. Large arrow = radial tuberosity, arrowheads = distal biceps tendon, small arrow = musculotendinous junction.

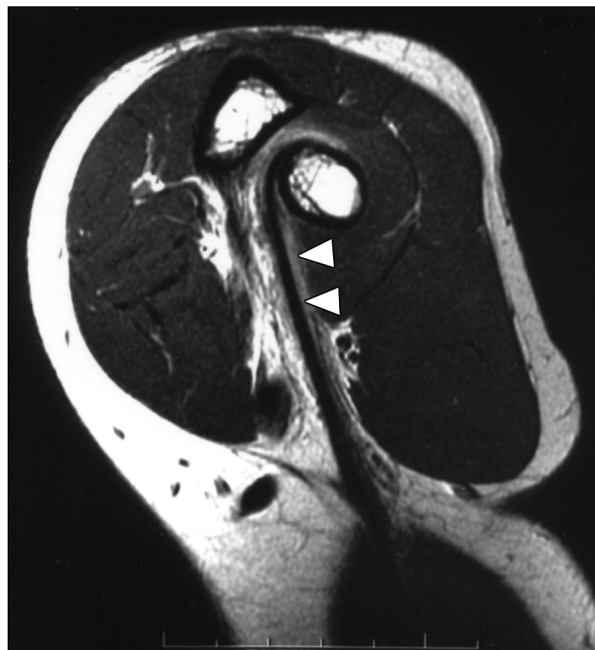


Fig. 4.—49-year-old man with partial tear of right distal biceps brachii tendon. Proton density-weighted MR image (TR/TE, 3,000/34) of flexed abducted supinated view of partial tendon tear shows linear abnormal signal adjacent to intact tendon extending from insertion to mid part of tendon and blurring of fat adjacent to tendon. Arrowheads = linear abnormal signal in distal tendon.

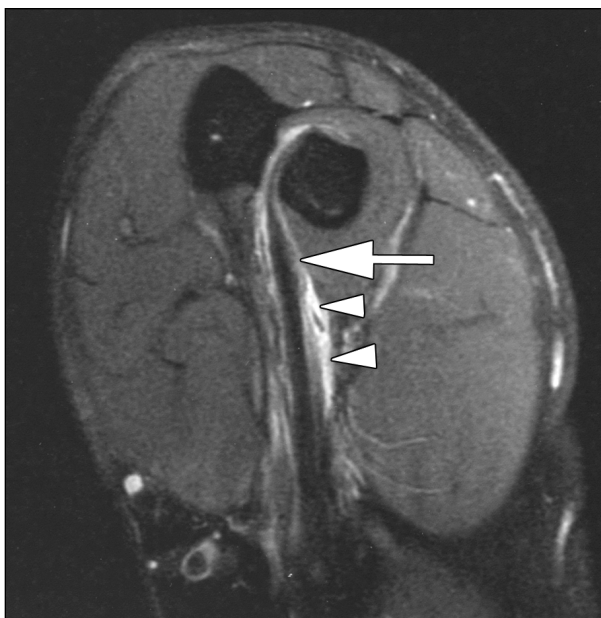

Fig. 5.—53-year-old man with partial tear of right distal biceps brachii tendon. Proton density fat-suppressed MR image (TR/TE, 3,000/45) shows flexed abducted supinated view with partial tear and fluid around tendon. Arrow = abnormal signal of partial tear, arrowheads = fluid around distal tendon.

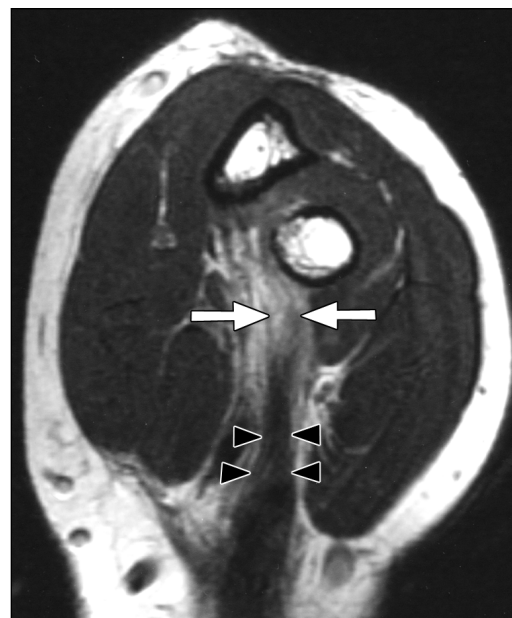

Fig. 6.—49-year-old man with complete tear of left distal biceps brachii tendon. Proton density-weighted MR image (TR/TE, 3,000/34) of flexed abducted supinated view of complete tendon tear shows discontinuity of tendon and abnormally thickened proximal part of tendon. Arrows = gap as result of complete tear, arrowheads = thickened remaining distal biceps brachii tendon.

Complete rupture is often an avulsion from the radial attachment and is often clinically evident. The differentiation of complete tears from partial tears is sometimes confusing clinically, particularly if the lacertus fibrosis remains intact. The treatment of complete tears without retraction or partial tears can benefit from precise delineation of the extent of the abnormality [3, 7]. MRI of distal biceps brachii tendon tears has been described in several articles [3, 7, 8].

MRI of the distal biceps brachii tendon is often difficult because of the anatomic course of the tendon close to its insertion. Studies have described several different methods of patient positioning for optimally imaging the elbow using MRI [3–8]. The patient is usually most comfortable supine with the arms by the sides. The off-axis position of the arm makes fat suppression poor with resultant variable signal homogeneity. Problems also occur with obese or large-framed patients in whom difficulty fitting the coil and patient into the confined space of the magnet bore is experienced. One alternative described involves positioning the patient supine or prone with the arm outstretched above the head, elbow extended, and forearm supinated [4]. The signal strength and homogeneity are superior in this overhead position.

Sagittal images through the distal biceps brachii tendon may be difficult to interpret because of partial volume-averaging effects due to the oblique course of the tendon to its insertion.

Flexion of the elbow is associated with contraction of the biceps muscle belly, and the tendon is taut. With the forearm supinated, the radial tuberosity is directed medially and with the elbow flexed, the distal tendon is in an almost direct line from the muscle belly to its insertion. The flexed abducted supinated view successfully achieves a longitudinal view of the distal biceps brachii tendon often in one section, including the difficult-to-assess insertion on the radial tuberosity. Because the tendon is assessed longitudinally and is at full length, the differentiation of partial from complete tears is made easier. The position of the elbow near the center of the magnet makes fat suppression optimal, enhancing visualization of small amounts of fluid.

The traditional axial image of the distal biceps brachii tendon is also a valuable means of assessing this structure. Aside from providing a short-axis image of the tendon, the axial series provides a familiar view of the important associated structures such as the median and radial nerves at the elbow.

In conclusion, the flexed abducted supinated view provides a reproducible technique for MRI of the distal biceps brachii tendon, obtaining a longitudinal image of the tendon from the musculotendinous junction to its insertion, often in one section.

Acknowledgments

We thank David Connell for his inspiration for this positioning and Sandy Huggett, radiographic technologist, Royal North Shore Hospital and Tim McLellan, radiographic technologist, North Shore Radiology, for their assistance with this work.

References

1. Agins HJ, Chess JL, Hoekstra DV, Teitge RA. Rupture of the distal insertion of the biceps brachii tendon. *Clin Orthop* 1988;234:34–38
2. Bourne MH, Morrey BF. Partial rupture of the distal biceps tendon. *Clin Orthop* 1991;271:143–148
3. Fitzgerald SW, Curry DR, Erickson SJ, Quinn SF, Friedman HF. Distal biceps tendon injury: MR imaging diagnosis. *Radiology* 1994;191:203–206
4. Holtz P, Erickson SJ, Holmquist K. MR imaging of the elbow: technical considerations. *Semin Musculoskelet Rad* 1998;2:121–132
5. Kneeland JB. MR imaging of the elbow: technical considerations. *Magn Reson Imaging Clin N Am* 1997;5:439–442
6. Ho CP. MR imaging of tendon injuries in the elbow. *Magn Reson Imaging Clin N Am* 1997;5:529–543
7. Falchhook FS, Zlatkin MB, Erbacher GE, Moulton JS, Bisset GS, Murphy BJ. Rupture of the distal biceps tendon: evaluation with MR imaging. *Radiology* 1994;190:659–663
8. Williams BD, Schweitzer ME, Weishaupt D, et al. Partial tears of the distal biceps tendon: MR appearance and associated clinical findings. *Skeletal Radiol* 2001;30:560–564